

# Identifying murder victims with endodontic radiographs

Rhonan Ferreira Silva<sup>1,2</sup>,  
Ademir Franco<sup>3</sup>,  
Solon Diego Santos  
Carvalho Mendes<sup>2</sup>,  
Fernando Fortes Picoli<sup>2</sup>,  
Fernando Gomes Nunes<sup>4</sup>,  
Carlos Estrela<sup>5</sup>

<sup>1</sup>Department of Forensic  
Odontology, Federal University  
of Goiás, <sup>2</sup>Department of Legal  
Odontology and Forensic  
Anthropology, Scientific Police of  
Goiás, <sup>4</sup>Department of Forensic  
Odontology, School of Dentistry,  
Paulista University, Goiás,  
<sup>3</sup>Department of Endodontics,  
Federal University of Goiás,  
Goiânia, Goiás, Brazil, <sup>3</sup>Department  
of Forensic Odontology, Katholieke  
Universiteit Leuven, Leuven,  
Belgium

**Address for correspondence:**  
Prof. Rhonan Ferreira Silva,  
Federal University of Goiás,  
Forensic Odontology, Praça  
Universitária s/nº, Setor  
Universitário, CEP 74605-220,  
Goiânia, Goiás, Brazil.  
E-mail: rhonanfs@terra.com.br

## Abstract

Endodontics is a special branch of dentistry constantly guided by imaging examinations. From a forensic scope, endodontics plays a valuable role providing solid antemortem (AM) radiographic evidence for comparison with postmortem findings in human identifications. This study illustrates the interface between endodontics and forensic odontology describing three cases of human identification based on radiographic endodontic records. From 2009 to 2012, three unknown male victims of murder were examined in a local Brazilian medico-legal institute to retrieve identity and potential cause of death. Specifically, when asked for AM data, a relative of the three victims provided periapical radiographs of endodontic treatments. Based on that, forensic dentists reproduced the same imaging acquisition techniques obtaining similar periapical radiographs, enabling a comparative dental identification. All the victims were positively identified based on patterns of dental morphology and treatment intervention. This study draws the attention of general and forensic dentists highlight the importance of properly recording dental treatments and searching for evidence in AM endodontic data, respectively.

**Key words:** Dental radiography, endodontics, forensic dentistry, human identification

## Introduction

Forensic odontology is a special branch of dentistry that works in parallel with the courts, providing evidence to elucidate civil and criminal circumstances.<sup>[1]</sup> Specifically, forensic dentists play an essential part in the identification of charred, putrefied, decomposed bodies, as well as of skeletal remains, in which fingerprints are no longer available.<sup>[2]</sup>

The dental identification of humans is often performed through a comparative approach.<sup>[2]</sup> Basically, antemortem (AM) data obtained from records of dental treatments (e.g. radiographs, written records, dental casts, and photographs) are collected from private clinics and compared with postmortem (PM) data obtained during cadaveric examinations.<sup>[3]</sup> In this context, endodontics emerges as a potential source of AM data, once the steps

Access this article online	
Website: www.jfds.org	Quick Response Code
DOI: 10.4103/0975-1475.195112	

This is an open access article distributed under the terms of the Creative Commons Attribution-NonCommercial-ShareAlike 3.0 License, which allows others to remix, tweak, and build upon the work non-commercially, as long as the author is credited and the new creations are licensed under the identical terms.

**For reprints contact:** reprints@medknow.com

**How to cite this article:** Silva RF, Franco A, Mendes SD, Picoli FF, Nunes FG, Estrela C. Identifying murder victims with endodontic radiographs. J Forensic Dent Sci 2016;8:167-70.

of endodontic interventions are systematically recorded into the clinical files together with detailed registration of imaging examinations.<sup>[4]</sup> This specific source of AM data enables the detection of unique features, such as the radiographic morphology of the pulp chambers and root canals, the height of alveolar bone crests, the stage of root formation, and the presence of dilacerations and periapical lesions.<sup>[4,5]</sup>

The present study highlights the interrelationship between endodontics and forensic odontology, illustrating the usefulness of endodontic radiographic records as legal evidence for the dental identification of murder victims.

## Case Reports

This study describes three cases of unknown male victims of murder examined between 2009 and 2012, at the medico-legal institute of Goiás, Central-Western Brazil.

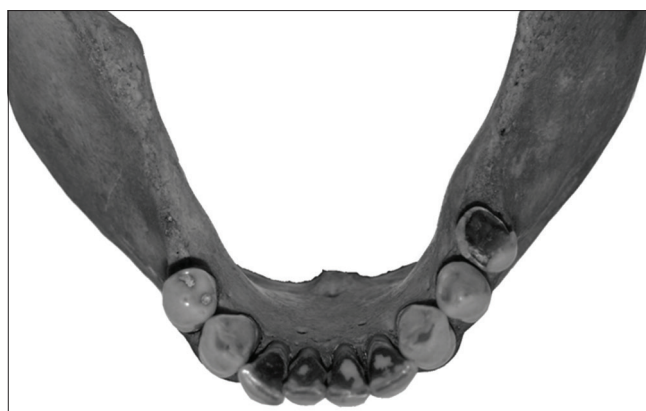### Case 1

In 2009, a highly decomposed body was found near a river. After crime scene investigation, the body was referred for an autopsy. Dental examination revealed a nonmetallic restoration in the mandibular left first premolar (#34), a decayed mandibular left second premolar (#35), a metallic restoration in the mandibular right first premolar (#44), and missing molars [Figure 1]. The mandible was dissected to allow adequate PM radiographic examination, which revealed root canal treatment in the tooth #34 [Figure 2].

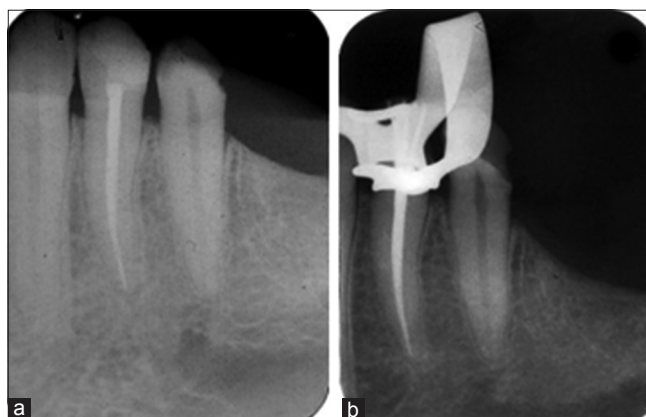
Police investigations suggested that the body belonged to a 30-year-old man, missing for 15 days. Relatives of the potential victim were asked to provide any AM medical record. Periapical radiographs dated from 2008 were obtained and showed evidence of root canal treatment performed in the tooth #34 [Figure 2]. Moreover, both AM (2008) and PM (2009) radiographs showed the same morphology of the mandibular left first and second premolars, as well as missing molars. Additional similarities were detected when analyzing alveolar bone loss in the region of the mandibular left molars.

### Case 2

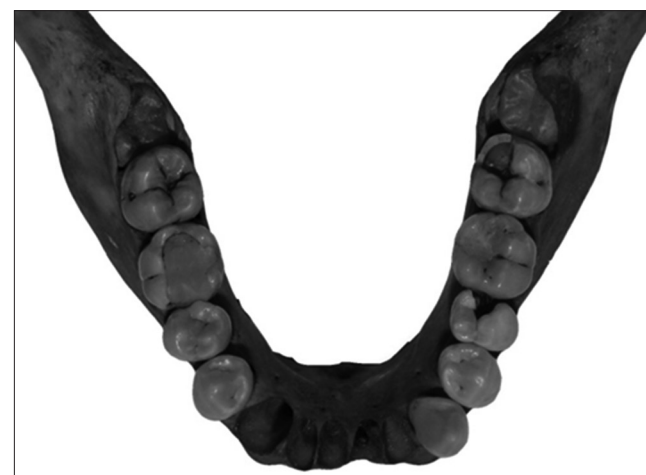In 2011, a body was also found in highly decomposed state, again near a river. Dental autopsy revealed several decayed teeth; teeth restored with nonmetallic materials; and empty sockets in the anterior region of the mandible [Figure 3]. Radiographically, the victim presented slight dilaceration of the mandibular right second premolar (#45); root canal treatment in the mandibular right first molar (#46); incomplete root development of the mandibular right second (#47) and third molars (#48); and alveolar bone crest extending obliquely from the mandibular right second premolar (#45) to the mandibular right first molar (#46) [Figure 4].



**Figure 1:** Postmortem photograph of the mandible of the victim in case 1 (2009)



**Figure 2:** Comparison between (a) postmortem (2009) and (b) ante-mortem (2008) periapical radiographs, revealing root canal treatment in the mandibular left first premolar and similar morphological structure adjacent to the mandibular left second premolar



**Figure 3:** Postmortem photograph of the mandible of the victim in case 2 (2011)

The search for compatible AM data resulted in endodontic pre- and post-operative periapical radiographs, dated from 2009, related to the treatment of the tooth #46 [Figure 4]. In addition, the images revealed that the teeth #45, #47, and #48 presented incomplete root development. Alveolar

bone crest extending obliquely from the tooth #45 to the tooth #46 was also detected. Positive dental identification was achieved considering the matching evidence of dental interventions (endodontic treatment) and morphological traits. Additional confirmation was obtained in the dental age estimation process, which revealed a time interval of approximately 2 years for root development of the teeth #47 and #48, compatible with the period elapsed from 2009 to 2011.

### Case 3

In 2012, a body was found in the countryside. Anthropological examinations on the skull and pelvic bones indicated compatibility with an unknown adult male. On dental autopsy, only a maxillary right first molar (#16) with a metallic crown was detected [Figure 5]. Radiographically, endodontic treatment of the tooth #16 was detected, as well as an impacted maxillary canine (#13) transversely positioned [Figure 6].

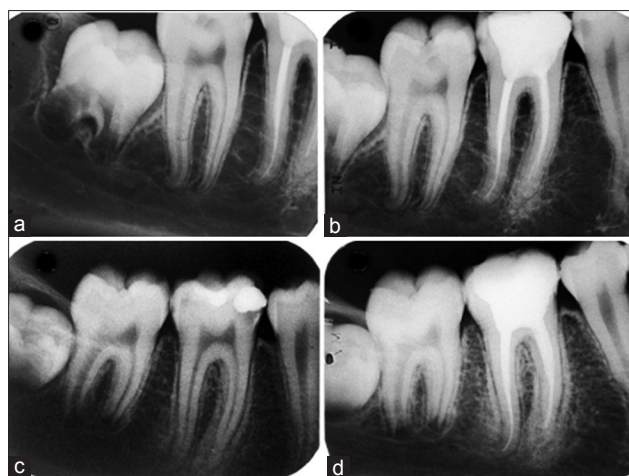
Police investigations indicated an initial compatibility between the skeletal remains and a 45-year-old male, missing for 60 days. Relatives of the potential victim provided periapical radiographs and a clinical file containing details of endodontic interventions performed in 2008. Moreover, radiographs establishing endodontic working length, and assessing the postoperative outcome of the tooth #16, revealed the apex of the tooth #13 [Figures 6]. Both teeth presented unique traits, which positively matched PM findings during the comparative procedure, leading to the positive identification of the victim.

### Discussion

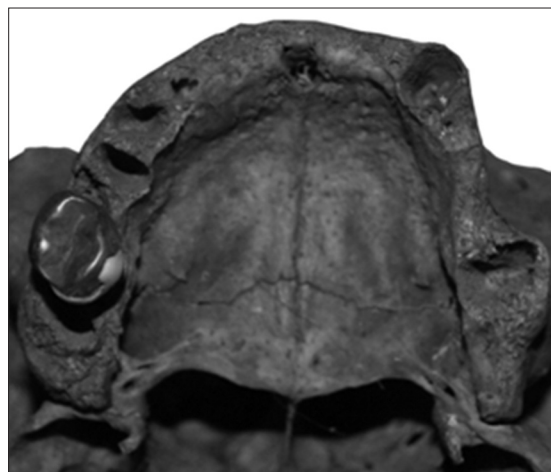
Over the last few decades, an increasing interest in the relationship between endodontics and forensic odontology arose. Mostly, this interest is justified due to the fact that endodontics constantly requires radiographic recording of clinical steps;<sup>[3]</sup> while forensic odontology constantly depends on radiographic evidence for strongly supported positive identifications.

Forrest and Wu,<sup>[3]</sup> 2010, have highlighted that radiographs are the most reliable source of AM data for human identifications, as they enable comparison with PM findings. In addition, tooth roots preserve morphological information for a longer time when compared with dental crowns,<sup>[3]</sup> which constantly undergo dental interventions. During endodontic treatment planning, this morphological information is radiographically recorded, and can be later used for forensic purposes.

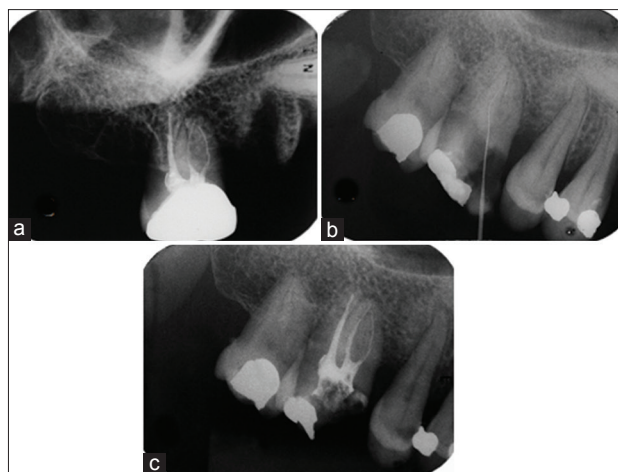
In the cases here described, radiographic endodontic records were useful and allowed the positive identification of victims based on evidence of root canal treatments and morphological features. Similarly, Spyropoulos and



**Figure 4:** Comparison between (a and b) postmortem (2011) and (c and d) ante-mortem (2009) periapical radiographs, revealing endodontic treatment in the mandibular right first molar, dilaceration of the mandibular right second premolar, and incomplete root formation in the mandibular right third molar



**Figure 5:** Postmortem photograph of the maxilla of the victim in case 3 (2012)



**Figure 6:** Comparison between (a) postmortem (2012) and (b and c) ante-mortem (2008) endodontic radiographs, revealing endodontic treatment in the maxillary right first molar and the apex of a transversely impacted maxillary right canine



Liakakoy,<sup>[5]</sup> 1990, achieved positive human identification using radiographic information from a single maxillary right second premolar. Years later, Weisman,<sup>[6]</sup> 1996, contributed to the medical literature publishing a case of positive identification based on the interface between forensics and endodontics. Recently, Silva *et al.*,<sup>[4]</sup> 2014, reported a positive human identification based on the combination of unique morphological features of the maxillary sinus; root canal treatment; and missing teeth detected in periapical endodontic radiographs, confirming the forensic potential within this source of evidence.

Importantly, human identification using dental radiographs has limitations related to the type of body examined and the quality of the AM records used in the forensic odontology examination.

In the decomposed and skeletonized bodies, the teeth and dental materials present in the PM examination are more preserved and generally can be compared with the AM radiographs.<sup>[4]</sup> However, in cases of charred bodies, the teeth, and endodontic materials can be degraded, and a comparative morphological analysis would not be possible, although endodontic materials can be tracked even when exposed to high temperatures.<sup>[7,8]</sup>

Another limitation for the success of dental identification using endodontic radiographs is the absence of these records or when they are present, they were produced in low quality, or with inadequate technique or the archiving was incorrect.<sup>[9]</sup> Therefore, the professional has an ethical and legal obligation to produce the dental radiographs (conventional or digital) and stores them properly, especially for use in forensic purposes.<sup>[10]</sup>

In Brazil, the Dental Code of Ethics<sup>[11]</sup> requires that dentists archive the dental records of their patients indefinitely,<sup>[12]</sup> and the violation of the ethical standards set forth in the document may result in penalties that range from a warning to revocation of professional license.

## Conclusion

The increasing trend of performing human identification supported by endodontic evidence indicates that justice is aware of the usefulness of endodontics as a source of AM

data. As a result, endodontists may be asked to support the law in the face of violent crimes, especially murders. Based on that, awareness of the importance of performing adequate radiographic techniques and recording them becomes essential. Moreover, dentists should keep up with new technologies for the management of conventional and digital radiographs, and for the proper recording and storing of endodontic data.

## Financial support and sponsorship

Nil.

## Conflicts of interest

There are no conflicts of interest.

## References

1. Silva RF, Nunes FG, Faria Neto JC, Rege IC, Junior ED. Forensic importance of panoramic radiographs for human identification. *Rev Gaucha Odontol* 2012;60:527-31.
2. Silva RF, Franco A, Dias PE, Gonçalves AS, Paranhos LR. Interrelationship between forensic radiology and forensic odontology – A case report of identified skeletal remains. *J Forensic Radiol Imaging* 2013;1:201-6.
3. Forrest AS, Wu HY. Endodontic imaging as an aid to forensic personal identification. *Aust Endod J* 2010;36:87-94.
4. Silva RF, Franco A, Picoli FF, Nunes FG, Estrela C. Dental identification through endodontic radiographic records: A case report. *Acta Stomatol Croat* 2014;48:147-50.
5. Spyropoulos ND, Liakakoy P. The use of periapical x-rays in the identification of a corpse. *Hell Stomatol Chron* 1990;34:151-6.
6. Weisman MI. Endodontics – A key to identification in forensic dentistry: Report of a case. *Aust Endod J* 1996;22:9-12.
7. Savio C, Merlati G, Danesino P, Fassina G, Menghini P. Radiographic evaluation of teeth subjected to high temperatures: Experimental study to aid identification processes. *Forensic Sci Int* 2006;158:108-16.
8. Bonavilla JD, Bush MA, Bush PJ, Pantera EA. Identification of incinerated root canal filling materials after exposure to high heat incineration. *J Forensic Sci* 2008;53:412-8.
9. Kavitha B, Einstein A, Sivapathasundharam B, Saraswathi TR. Limitations in forensic odontology. *J Forensic Dent Sci* 2009;1:8-10.
10. Charangowda BK. Dental records: An overview. *J Forensic Dent Sci* 2010;2:5-10.
11. Brazilian Federal Council of Dentistry. Brazilian Code of Dental Ethics. Rio de Janeiro: CFO-Brazil; 2012.
12. Paranhos LR, de Magalhães MP, Francio J, Terada HH, Rosário HD, da Silva RF. Time of guard of orthodontic records versus legal time for their prescription. *Dental Press J Orthod* 2013;18:113-7.