

Denture barcoding in forensic dentistry: A future option

Jayaprakash Mugur

Basavanna,

Abhishek Jain,

Sumit Kumar Misra

*Department of Prosthodontics
and Implantology, Teerthanker
Mahaveer Dental College and
Research Center, Moradabad,
Uttar Pradesh, India*

Address for correspondence:

Dr. Jayaprakash Mugur

Basavanna,

*Department of Prosthodontics
and Implantology, Teerthanker
Mahaveer Dental College and
Research Center, Delhi Road,
Bagarpur, Moradabad - 244 001,
Uttar Pradesh, India.*

*E-mail: drjayaprakashmb@gmail.
com*

Abstract

Neurodegenerative disorders are commonly seen in elderly individuals. Parkinson's disease (PD) is the most common example with memory loss, lack of logic, reasoning and analytical thinking. In this case report simple method of 2D Bar code technique of denture marking has been explained which will not only useful in patients with memory loss but it is very helpful in identifying the individuals in case of natural calamities like floods, earthquake, tornado, state of unconsciousness and accidents. Such patients can be traced easily by denture barcoding. This technique is a major breakthrough in the field of forensic dentistry.

Key words: Bar code, denture identification, neurodegenerative disorders, Parkinson's disease

Introduction

“Denture identification systems are important for hospitalized patients, patients in long-term care facilities, for forensic identification purposes, and other social reasons.”^[1-3] “At times the only identifiable remains are a victim's partial or complete dentures.”^[4]

Denture marking assists in the return of a lost denture and facilitates the identification of either a living or a deceased denture wearer.^[5]

Parkinson's disease is the most common example of neurodegenerative disorders as there is dysfunctions of memory, logic, reasoning, and analytical thinking, these patients can be traced easily by labeling their prostheses.^[6]

This study illustrates a simple technique for the incorporation of a 2-dimensional (2-D) bar code into the denture and describes its significance in the field of forensic dentistry.

Case Report

A 65-year-old male patient reported to the Department of Prosthodontics with the chief complaint of needing to replace his missing teeth. The patient had a history of Parkinson's disease since 10 years and was on medication. Extraoral examination revealed a typical “mask-like” appearance of the face due to reduction in the movements of the facial muscles. The eyes were dry and had a fixed gaze [Figure 1].

Restricted lip movement was observed. There was a typical “pill-rolling” movement between thumb and fingers. The tremors spread to the legs, the face, the tongue, and the mandible.

Patient management

Before starting the treatment consent was taken from the patient by the physician.

The primary impression was recorded using putty impression (Aquasil, DENTSPLY/Caulk, Germany) [Figure 2]

Access this article online

Website:

www.jfds.org

DOI:

10.4103/0975-1475.176952

Quick Response Code



Type III dental stone (Kalabhai Dental Pvt. Ltd., Mumbai, India) was used to pour the primary cast.

Single-step border molding was done using polyvinyl siloxane impression material of putty consistency (Aquasil, DENTSPLY/Caulk). The final impression was recorded using light-bodied polyvinyl siloxane impression material (Aquasil, DENTSPLY/Caulk) [Figure 3].

Jaw relation was recorded tentatively because of poor neuromuscular control resulting in uncoordinated mandibular movements and variable centric relation. Hence, monoplane teeth were selected [Figure 4]. Try-in was done.

Incorporation of 2-D bar code

A 2-D bar code with details such as name, gender, age, address, phone number, and medical history was generated with a code generator (QR2, Kaywa-Code Generator, beta v1.000, Kaywa AG, Zurich, Switzerland).

- The 2-D bar code label of 10 × 10 mm in size was printed on paper and laminated
- The laminated code was then embedded between thin films of clear autopolymerizing acrylic resin (DPI-RR Cold Cure DPI Products and Services Limited, Mumbai, India) [Figure 5]
- The bar code was positioned on the palatal surface of the maxillary denture after the trial closure, and then curing was done in a conventional manner (prefabrication technique) [Figure 6]

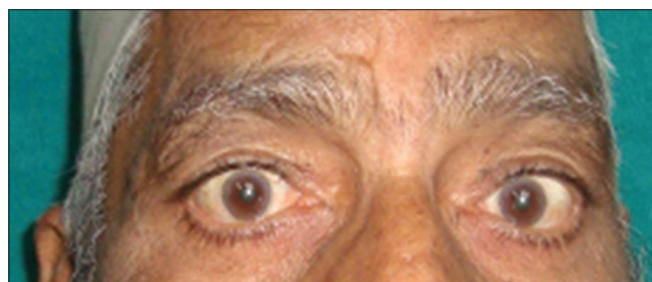

Figure 1: Fixed gaze of the patient

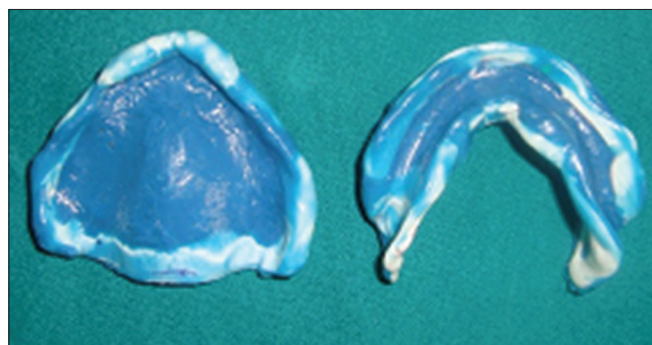


Figure 3: Maxillary and mandibular final impressions

- For the mandibular denture, the label was positioned in a recess created 1 mm deep on the distolingual flange of the denture. Note that the marker may fail to decode if placed on a deep curved surface (postfabrication technique) [Figure 7]
- The recess was filled with clear autopolymerizing acrylic resin before trimming and polishing [Figure 8]
- A code decoder (i-nigma, v3.10.02, 3GVision, Yehuda, Israel) enabled mobile camera was held against the label for the code to be deciphered [Figure 9]
- After a few seconds the recognized code was translated into text on a mobile screen displaying the patient's data [Figure 10]
- Denture insertion was done [Figure 11].

Discussion

It is a well-documented practice to mark dentures with surface inscription and inclusion markers.^[4]

The identification of dentures may also be needed in places such as senior citizen centers or hospitals.^[7]

It is obvious that only marked dentures can reveal the positive identity of a person when all other methods fail to do so. This in itself is reason enough to justify the implementation of marking of dentures.^[8,9]

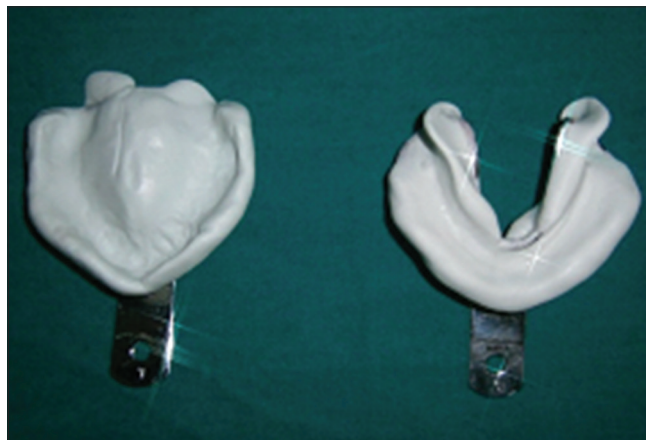

Figure 2: Maxillary and mandibular preliminary impressions

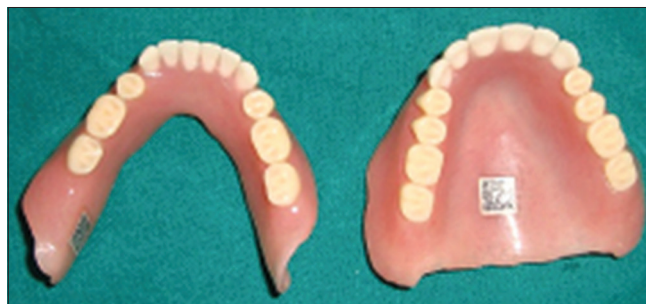

Figure 4: Maxillary and mandibular dentures showing monoplane teeth



Figure 5: Laminated 2D bar code

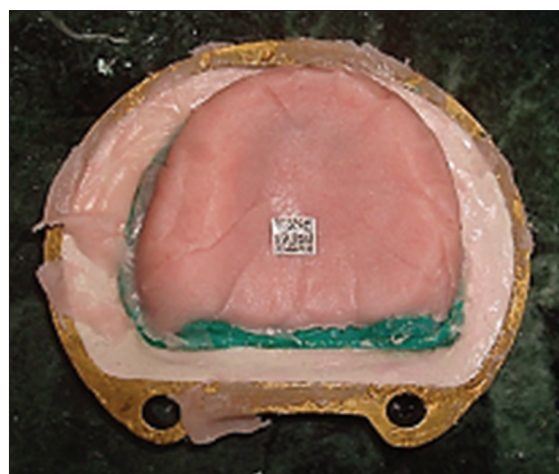


Figure 6: Bar code positioned on palatal surface of maxillary denture

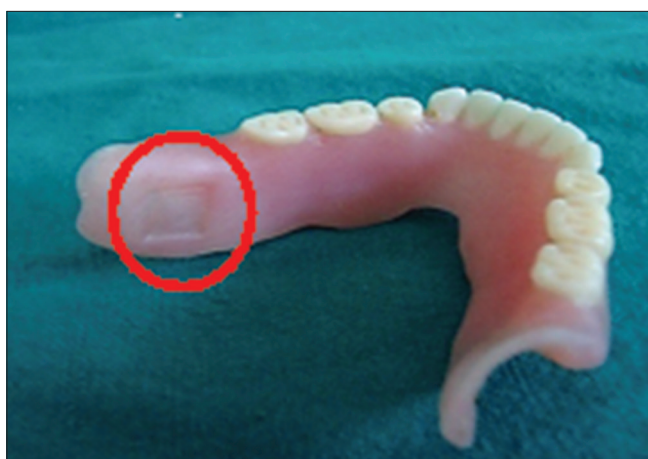

Figure 7: Recess on the cameo surface on the disto-lingual flange of the mandibular denture

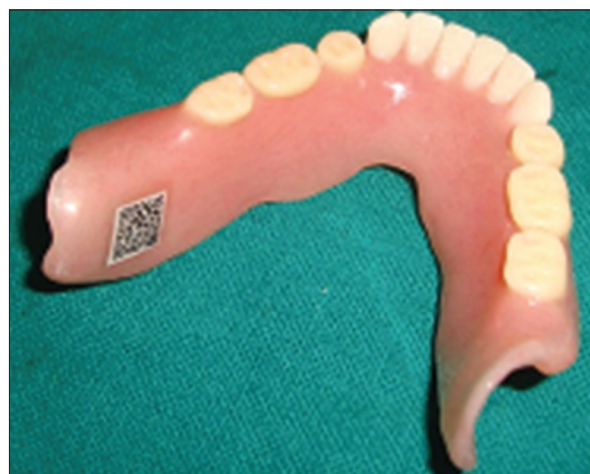

Figure 8: Recess filled with clear auto polymerizing acrylic resin.

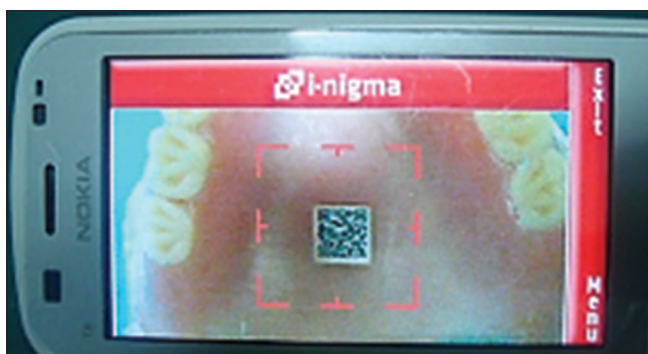

Figure 9: Bar code reader enabled mobile camera held against the denture

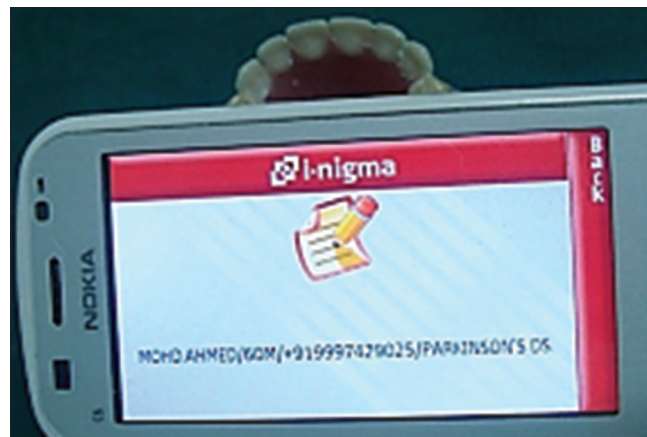


Figure 10: Mobile screen displaying the patient's data

The proposed method allows individual information to be recorded easily in dental offices and private dental laboratories.

Individuals suffering from Parkinson's disease, Alzheimer's disease, or any neurodegenerative disorders resulting in dementia are prone to wandering.^[10] To protect these

vulnerable individuals a 2-D bar code can be incorporated into their prostheses.

Labeling of dentures is recommended by most international dental associations and forensic odontologists.^[11,12] In

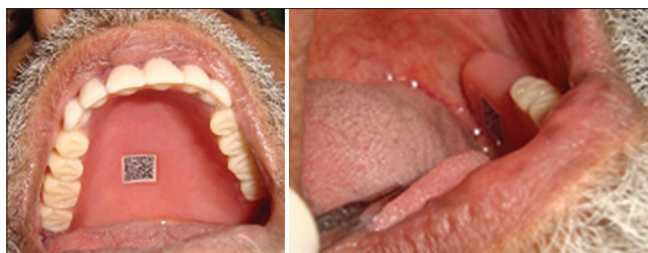

Figure 11: Maxillary and mandibular labelled dentures in patient's mouth

the near future personal wander monitoring technology falling under two categories, namely, radio frequency identification (RFID) and global positioning systems (GPS) can be incorporated into different kinds of prosthesis for easy tracking of patients with such neurological disorders.^[13]

The prefabrication techniques are more permanent, but induce points of weakness unless they are bonded to the acrylic resin.^[1] Thus it is a technique-sensitive procedure. On the other hand, postfabrication techniques are quicker and easier but they are not permanent and may fade after subsequent use of the denture compared to the prefabrication techniques.

In this clinical trial both pre and postfabrication techniques were followed and the labels were inserted in a preparation site, which is located in the flattest portion on the cameo surfaces of the distolingual flange of the mandibular denture and the palate of the maxillary denture.^[4,5] Denture markers should be positioned in such areas where they do not interfere with either the esthetics or the function of the denture. These areas are also unaltered during postinsertion adjustments and routine wear and tear or relining procedures.^[14] Hence these areas were considered for the positioning of a 2-D bar code.

Conclusion

Denture barcoding plays an important role in identifying the person in case of an accident, dementia, state of unconsciousness, missing individuals, or in identifying dead bodies in natural calamities. A variety of denture marking systems have been reported in the literature. The present clinical report describes the incorporation of a 2-D bar code into the prostheses in a patient with a neurodegenerative disorder. This procedure is simple,

reliable, and cost effective, thus paving a new path for identification in forensic dentistry.

Declaration of patient consent

The authors certify that they have obtained all appropriate patient consent forms. In the form the patient(s) has/have given his/her/their consent for his/her/their images and other clinical information to be reported in the journal. The patients understand that their names and initials will not be published and due efforts will be made to conceal their identity, but anonymity cannot be guaranteed.

References

1. Ling BC. Computer-printer denture micro labeling system. *J Prosthet Dent* 1998;79:363-4.
2. Lamb DJ. A simple method for permanent identification of dentures. *J Prosthet Dent* 1992;67:894.
3. Mahoorkar S, Jain A. Denture identification using unique identification authority of India barcode. *J Forensic Dent Sci* 2013;5:60-3.
4. Richmond R, Pretty IA. Contemporary methods of labeling dental prostheses - A review of the literature. *J Forensic Sci* 2006;51:1120-6.
5. Richmond R, Pretty IA. Denture marking-patient preference of various methods. *J Forensic Sci* 2007;52:1338-42.
6. Harrison's Principles of Internal Medicine. Kasper DL, Fauci AS, Longo DL, Braunwald E, Hauser SL, Jameson JL, editors. 16th ed. New Delhi: McGraw-Hill; 2005. p. 2406-7.
7. Rajendran V, Karthigeyan S, Manoharan S. Denture marker using a two-dimensional bar code. *J Prosthet Dent* 2012;107:207-8.
8. Bushick RD. Forensic dentistry: An overview for the general dentist. *Gen Dent* 2006;54:48-53.
9. Datta P, Sood S. The various methods and benefits of denture labeling. *J Forensic Dent Sci* 2010;2:53-8.
10. Rajeswari CL. Prosthodontic considerations in Parkinson's disease. *PJSR* 2010;3:45-7.
11. The ABFO Identification Guidelines. Home page 2006. Available from: http://www.forensicdentistryonline.org/Forensic_pages_1/ident_guidelines.htm. [Last accessed on 2010 Sep 14].
12. Alexander PM, Taylor JA, Szuster FS, Brown KA. An assessment of attitudes to, and extent of, the practice of denture marking in South Australia. *Aust Dent J* 1998;43:337-41.
13. Secure Care Products LLC. Active RFID vs GPS Alzheimer's Tracking Devices. Available from: <http://www.securecare.com/resources/active-rfid-vs-gps-alzheimers-tracking>. [Last accessed on 2010 Sep 14].
14. Berry FA, Logan GI, Plata R, Riegel R. A postfabrication technique for identification of prosthetic devices. *J Prosthet Dent* 1995;73:341-3.

How to cite this article: Basavanna JM, Jain A, Misra SK. Denture barcoding in forensic dentistry: A future option. *J Forensic Dent Sci* 2016;8:52-5.

Source of Support: Nil, **Conflict of Interest:** None declared